

# Primary Manifestation of Sarcoidosis Involving the Gingivae

Catherine Saylor, Nabil Beaini, James Rokos, Keerthana Satheesh, Charles Cobb

## ABSTRACT

Sarcoidosis of the gingiva is rarely the primary manifestation of the disease. The following case presentation highlights clinical signs and symptoms that are not uncommon or unusual except for the anatomical location of the initial expression. Appropriate treatment must be based on a definitive diagnosis which, in turn, requires a biopsy for histologic analysis.

**Keywords:** Sarcoidosis, Gingivae, Oral cavity.

**How to cite this article:** Saylor C, Beaini N, Rokos J, Satheesh K, Cobb C. Primary Manifestation of Sarcoidosis Involving the Gingivae. *Int J Experiment Dent Sci* 2012;1(2):102-105.

**Source of support:** Nil

**Conflict of interest:** None

## INTRODUCTION

Sarcoidosis is a granulomatous disorder that is characterized by noncaseating granulomas that may affect any organ.<sup>1,2</sup> Frequently, bilateral hilar lymphadenopathy, pulmonary infiltration and cutaneous and ocular lesions are common manifestations.<sup>1,2</sup> This disease may have a multisystem presentation with 90% of cases having pulmonary manifestations.<sup>3</sup> Symptoms of pulmonary involvement are likely to include dyspnea, nonproductive cough, chest pain, wheezing and nasal congestion and hemoptysis.<sup>4</sup> Though the pulmonary system is the most commonly targeted organ system, only 43% of patients with this involvement have minimal symptoms and near normal results in lung function tests.<sup>4</sup> Multiple organs and progressive pulmonary involvement indicate a poor prognosis with a mortality rate of approximately 5% in such cases.<sup>5</sup>

Cutaneous involvement of sarcoidosis is common and has a reported incidence of 9 to 37%.<sup>6</sup> In the United States, African-Americans have a higher incidence and females are more likely to develop cutaneous sarcoidosis in comparison to males.<sup>7</sup> The peak onset of the disease is most often observed in adults between the ages of 20 and 29.<sup>8</sup> Skin lesions that contain sarcoid granulomas are histologically classified as specific lesions and often present in association with the chronic course of this disease. Nonspecific lesions may not present with the typical noncaseating granulomas, but are commonly noted with acute presentation of sarcoidosis.<sup>9,10</sup> Clinical presentations may be alopecia, erythroderma, subcutaneous nodules, erythema nodosum, macules, papules and plaques and lupus pernio.<sup>6</sup>

Involvement of the oral mucous membranes is unusual and distinctly rare: Tongue (23%), buccal mucosa and vestibule (23%), lip (23%), hard and soft palate (17%) and gingiva (14%) indicating that oral sarcoidosis affects any site of the oral mucosa excluding the floor of the mouth.<sup>11,12</sup> Sarcoidosis of the gingivae as the primary or initial clinical lesion must be considered highly unusual as there are relatively few reports of gingival sarcoidosis. Gingival sarcoidosis often appears as drug-induced gingivitis.<sup>13</sup> Oral mucosal involvement in sarcoidosis usually manifests after systemic symptoms develop.<sup>12</sup> Oral manifestations of sarcoidosis have been described and include multiple, nodular, painless, indistinct ulcerations of the gingiva, buccal mucosa, labial mucosae and palate. Biopsy of oral sarcoidosis lesions reveal noncaseating granulomas with associated multinucleate giant cells and a lymphocytic infiltrate.<sup>1,3</sup>

Other granulomatous diseases must be considered in the differential diagnosis, such as Wegener granulomatosis, Crohns disease or tuberculosis.<sup>1,3,14</sup> Treatment often involves the use of systemic corticosteroids when given early in the course of the acute disease.<sup>5</sup> Exact use of indications, dosing, duration of therapy and effect on the natural history of the disease remain unclear.<sup>5</sup> Other drug choices, such as antimalarial, immunosuppressive and anti-inflammatory drugs have been used with some success in improving symptoms and suppressing inflammation.<sup>15</sup> Treatment of sarcoidosis typically depends on the pulmonary function and severity of the symptoms. Patients with the acute disease may experience spontaneous resolution of the disease, undergo remission, or may not have symptoms significant enough to warrant treatment.<sup>5</sup> Thus, treatment of sarcoidosis is individualized based on severity of disease and symptoms. Accurate diagnosis of sarcoidosis can be a challenge to clinicians. This disease is a 'disease of uncertainty' in terms of its cause, presentation and clinical course.<sup>8</sup> Referred to as the 'great imitator', cutaneous sarcoidosis may mimic a wide array of dermatological conditions that may hinder the initial diagnosis by clinicians.<sup>8</sup> Diagnosis of sarcoidosis is established based upon history, pulmonary function tests, chest radiograph, hematology, biochemical investigations and histologic studies.<sup>1</sup> Thus, awareness of this condition is essential for practitioners as an alternative diagnosis.

## CASE REPORT

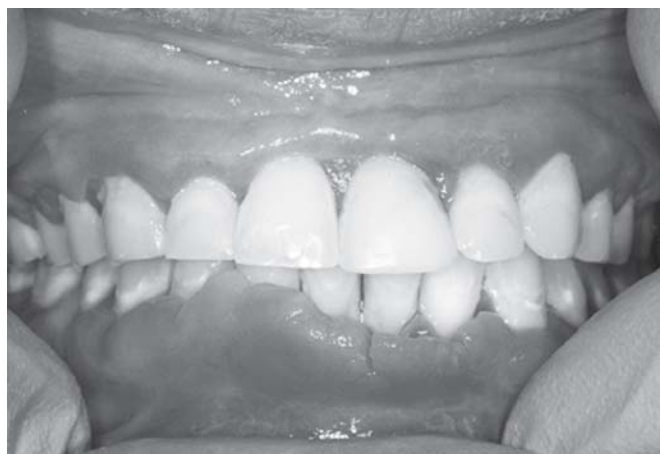In 2010, a 28-year-old Caucasian female was referred to the UMKC School of Dentistry, Graduate Department of Periodontics from the Oral Pathology Department concerning the patients' labial gingiva. This patient's chief complaint involved red, swollen gums located on the lower arch that were esthetically displeasing to her. Hypertrophic tissue, isolated to the labial gingiva on the lower arch was noted. This particular area had been excised before, as stated by the patient, but the tissue had regrown to the current state. No health history concerns or allergies were listed by this patient and hereditary factors did not contribute to the case. Evaluation of the area revealed that the patient had localized moderate periodontitis with isolated class III mobility on tooth number 24 (Fig. 1).

Past history revealed that a biopsy in this particular area had been taken in 2006. Erythematous hypertrophy of the gingiva had been present throughout the entire mouth for many years before this initial biopsy. It consisted of a  $1.0 \times 0.7 \times 0.3$  cm piece of tan, soft tissue from the buccal anterior

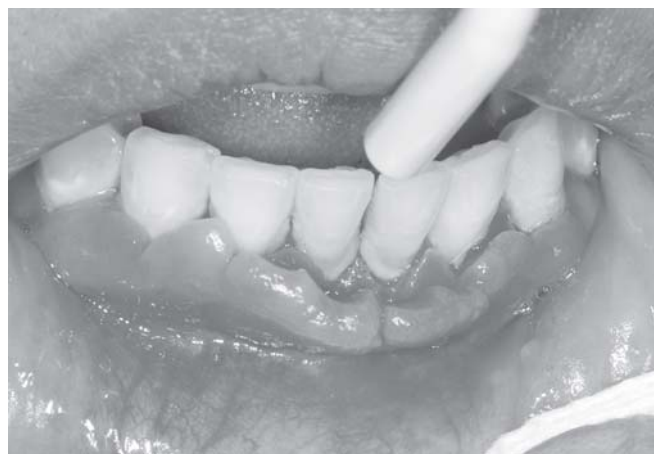mandible. The tissue exhibited a robust lymphoplasmacytic infiltrate and numerous giant cell foreign body granulomas. This was suggestive of foreign body gingivitis.

Presenting with a similar condition as in 2006, a second biopsy was obtained in 2010 on the labial mucosa/gingiva on teeth 21 to 28. The tissue presented with a more strawberry-like texture. Sections of the gingival mucosa exhibited a brisk lymphoplasmacytic infiltrate punctuated by numerous epithelioid granulomas. Birefringent foreign materials were identified in a few of the granulomas, but most were noncaseating and free of foreign body. Granulomatous gingivitis was the diagnosis with sarcoidosis being considered as a differential diagnosis.

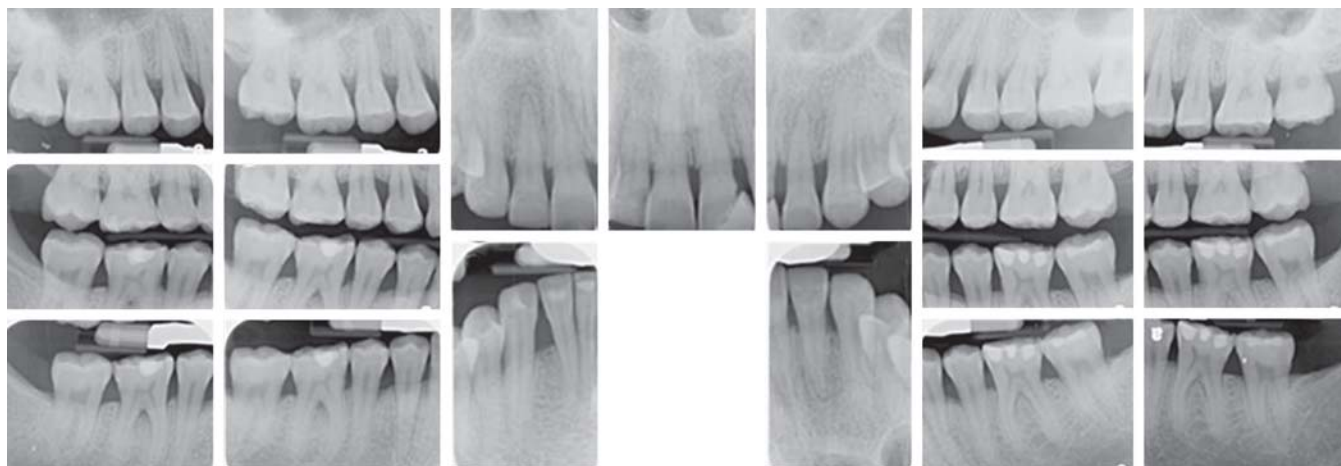
Presenting with further reddened, hyperplastic tissue with a granular surface texture and bone loss in 2011, a third and final biopsy was obtained (Figs 2 and 3). Within this specimen, the superficial lamina propria revealed numerous noncaseating, sarcoid-like granulomas with epithelioid cells and multinucleated giant cells in a background of a lymphoplasmacytic infiltrate (Figs 4 and 5).



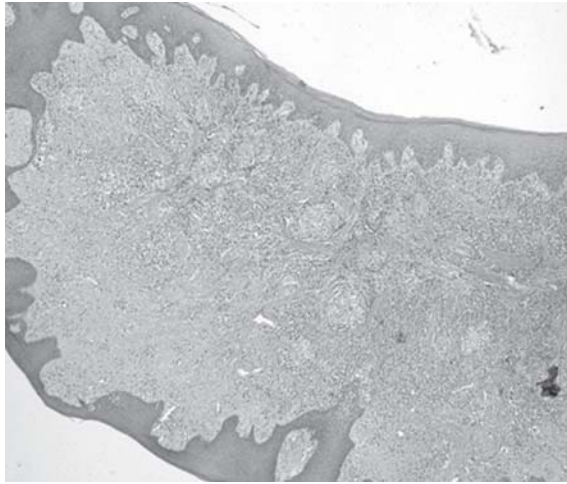
**Fig. 1:** Intraoral photograph of patients' mandibular anterior sextant taken in 2010



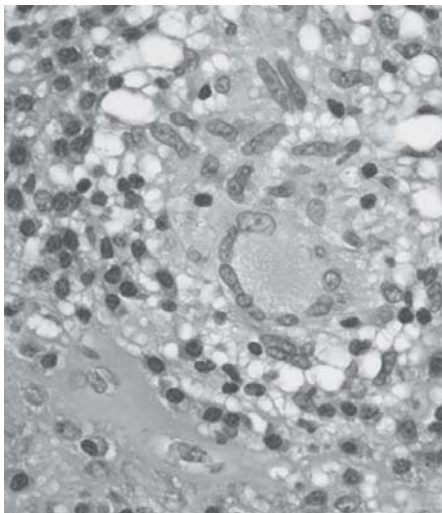
**Fig. 3:** Intraoral photograph of patients' lower anterior region from 2011



**Fig. 2:** Full mouth series of radiographs from 2009



**Fig. 4:** Low power view of a section of gingival tissue from 2011. The specimen is surfaced by mildly hyperplastic epithelium. Within the lamina propria, several noncaseating granulomas can be seen interspersed between bands of dense collagen and a florid chronic inflammatory cell infiltrate. Hematoxylin and eosin stained (original magnification:  $\times 50$ )



**Fig. 5:** High power view of a section of gingival tissue from 2011. This high power view shows the detail of one of the noncaseating granulomas. It is comprised of epithelioid histiocytes and a lymphoplasmacytic infiltrate. A prominent multinucleated giant cell can be seen on the center-right of the field. Hematoxylin and eosin stained (original magnification:  $\times 1,000$  oil)

Clinical information revealed hilar lymphadenopathy and the patient was referred to her physician for a computed tomographic (CT) examination of the chest. This revealed a nonspecific ground-glass opacity of the upper left lobe measuring 15 mm in dimension, noncalcified pulmonary nodules and a 7 mm nodular density of the left breast. The interpretation of the imaging, in conjunction with the clinical information, and the histopathology, confirmed the diagnosis of sarcoidosis. This patient was placed on a systemic corticosteroid regimen until further recommendations by the overseeing physician were given.

## CONCLUSION

Sarcoidosis is a disease of exclusion that mimics multiple alternative diseases. Though presentation of sarcoidosis in the oral cavity is rare, clinicians should be versed and aware of this condition as a possibility for diagnosis.

## REFERENCES

1. Antunes KB, Miranda AM, Carvalho SR, Azevedo AL, Tatakis DN, Pires FR. Sarcoidosis presenting as gingival erosion in a patient under long-term clinical control. *J Periodontol* 2008; 79(3):556-61.
2. Suresh L, Radfar L. Oral sarcoidosis: A review of literature. *Oral Dis* 2005;11(3):138-45.
3. Ho KC, Blair FM. Sarcoidosis of the gingiva—a case report. *Dent Update* 2003;30(5):264-68.
4. Batal H, Chou LL, Cottrell DA. Sarcoidosis: Medical and dental implications. *Oral Surg Oral Med Oral Pathol Oral Radiol and Endod* 1999;88(4):386-90.
5. Lazar CA, Culver DA. Treatment of sarcoidosis. *Semin Respir Crit Care Med* 2010;31(4):501-18.
6. Marchell RM, Judson MA. Cutaneous sarcoidosis. *Semin Respir Crit Care Med* 2010;31(4):442-51.
7. American Thoracic Society/European Respiratory Society. Statement on Sarcoidosis. Joint Statement of the American Thoracic Society (ATS), the European Respiratory Society (ERS) and the World Association of Sarcoidosis and other Granulomatous Disorders (WASOG) adopted by the ATS Board of Directors and by the ERS Executive Committee, February 1999. *Am J Respir Crit Care Med* 1999;160:736-55.
8. Ali MM, Atwan AA, Gonzalez ML. Cutaneous sarcoidosis: Updates in the pathogenesis. *J Euro Acad Dermatol and Venereol* 2010;24(7):747-55.
9. Mana J, Marcoval J. Erythema nodosum. *Clin Dermatol* 2007;25:288-94.
10. Yanardag H, Pamuk ON, Karayel T. Cutaneous involvement in sarcoidosis: Analysis of the features in 170 patients. *Respir Med* 2003;97:978-82.
11. Greer RO Jr, Sanger RG. Primary intraoral sarcoidosis. *J Oral Surg* 1977;35(6):507-09.
12. Kasamatsu A, Kanazawa H, Watanabe T, Matsuzaki O. Oral sarcoidosis: Report of a case and review of literature. *J Oral and Maxillo Surg* 2007;65(6):1256-59.
13. Blinder D, Yahatom R, Taicher S. Oral manifestations of sarcoidosis. *Oral Surgery Oral Med Oral Pathol Oral Radiol and Endod* 1997;83(4):458-61.
14. Fatahzadeh M, Rinaggio J. Diagnosis of systemic sarcoidosis prompted by orofacial manifestations: A review of the literature. *J Am Dental Assoc* 2006;137(1):54-60.
15. Coudill RF. Sarcoidosis of the gingiva: An elusive diagnosis. *Int J Perio and Rest Dent* 1988;8(2):66-74.

## ABOUT THE AUTHORS

### Catherine Saylor (Corresponding Author)

Dental/Dental Hygiene Education, Department of Periodontics UMKC School of Dentistry, Missouri, USA, e-mail: saylorcd@umkc.edu

**Nabil Beaini**

Graduate Student, Department of Periodontics, UMKC School of Dentistry, Missouri, USA

**James Rokos**

Assistant Professor, Department of Oral Pathology, UMKC School of Dentistry, Missouri, USA

**Keerthana Satheesh**

Assistant Professor, Department of Periodontics, UMKC School of Dentistry, Missouri, USA

**Charles Cobb**

Professor Emeritus, Department of Periodontics, UMKC School of Dentistry, Missouri, USA